

HLA antigens in lyophilised corneal lenticules

H. Tabandeh¹, E. Morris², C. K. Rostron¹ and C. Corbishley³

¹Department of Ophthalmology, ²Keratec Eye Bank, ³Department of Histopathology, St. George's Hospital, London SW17 0QT

ABSTRACT.

Purpose: To investigate the presence of Human Leukocyte Antigens (HLA) in organ cultured corneas, in lyophilised epikeratophakia lenticules prepared by dry state lathing, and in lenticules subjected to prolonged rehydration in Balanced Salt Solution (BSS).

Methods: Twelve lenticules and 3 organ cultured corneas were studied for the presence of HLA-ABC (class I), and HLA-DR, -DQ, and -DP (class II), antigens using the immunoperoxidase technique.

Results: HLA-ABC antigens were detected in all lenticules. HLA-DR antigen was also detected in low concentrations in 6 out of 12 lenticules. HLA-DQ and -DP antigens were generally absent. Incubation in BSS for 24 and 48 hours did not change the expression of antigens.

Conclusions: HLA-class I, and to some degree HLA-class II antigens, are present in the stroma of both organ cultured corneas, and in lyophilised lenticules. Incubation in BSS for up to 48 hours did not reduce the expression of antigens.

Key words: HLA antigens – corneal transplantation – lyophilised lenticules – epikeratophakia.

Acta Ophthalmol. Scand. 1998; 76: 653–657

Copyright © Acta Ophthalmol Scand 1998. ISSN 1395-3907

For the past 15 years epikeratophakia has been used for the surgical correction of refractive errors and in the treatment of keratoconus (Rostron 1996). During the period 1985–1992 corneal tissue lenticules for epikeratophakia were available from Allergan Medical Optics (AMO). These lenticules were prepared from corneas retrieved by eye banks in the USA, preserved for short periods in McCarey-Kaufman medium, and subsequently cryolathed and freeze-dried by AMO. Currently freeze-dried lenticules are produced in the Keratec Eye Bank using somewhat different processing protocols from those used in the past by AMO.

In the preparation of corneal tissue lenticules it has been shown that cryolathing will generally kill the corneal keratocytes unless cryoprotectants are used, and that the freeze-drying process inevitably kills the keratocytes (Zavala et al. 1985). From work in an experimental

animal model it has been shown that lyophilised corneal tissue is not rejected even in a pre-sensitised recipient host, whereas epikeratophakia lenticules prepared with fresh tissue may undergo rejection when transplanted onto a pre-vascularised cornea in a pre-sensitised recipient (Frantz et al. 1991). It would also appear from animal experimentation that lyophilised epikeratophakia lenticules do not sensitise the recipient to donor antigens (Moore et al. 1987). Certainly in humans there have been no reports of rejection of lyophilised corneal homografts, but it is not known whether the recipients become sensitised to donor antigens in epikeratophakia with lyophilised tissue. In an early report of patients undergoing penetrating keratoplasty after failed epikeratophakia there was an apparently increased rate of graft rejection of 43% (3 out of 7 cases) (Frantz et al. 1988). However, a subsequent report of a larger series of patients showed

a rejection rate of 13.6% (3 out of 22 cases) which is closer to the rejection rate expected in first time grafts (Frantz et al. 1989).

Apart from use in epikeratophakia, lyophilised corneal tissue has also been used for lamellar keratoplasty (Chau et al. 1992), and the possibility of patients requiring a subsequent penetrating re-graft also exists in this group if the lamellar graft is unsuccessful. Whether such patients are at greater risk of rejection of the penetrating graft is not known.

In a study of human lyophilised epikeratophakia lenticules prepared by AMO, Pepose and Benevento demonstrated the presence of HLA class I antigens at levels comparable to that of fresh central human cornea (Pepose & Benevento 1991). This finding supported results of earlier animal studies of Bourne (Bourne 1975), suggesting that there was no significant effect of cryopreservation on the antigenicity of corneal tissue.

Some studies have suggested that the antigenicity of corneal tissue may be altered by the removal of water soluble proteins by immersion of grafts in glycerol isotonic saline for one hour, and by mild denaturation of corneal proteins by other methods (e.g. lyophilisation) (Watanabe & Tsutsuio 1962). It is therefore possible that lenticules prepared by different techniques exhibit different antigenicity.

Lenticules prepared in the Keratec Eye Bank are made from corneas preserved in organ culture for a minimum of 4 weeks rather than short term storage at 4°C, and which are processed by dry state lathing rather than cryolathing, before subsequent freeze-drying. We set out to study the expression of antigens on lyophilised lenticules prepared in this way, and to determine whether washing the lenticules with BSS altered the antigenic expression.

Materials and Methods

Tissue preparation

Lyophilised lenticules were prepared from organ cultured donor corneas which could not be used for penetrating keratoplasty due to poor quality of the endothelium, or which could not be allocated to recipients within 4 weeks of being placed in organ culture. Lenticules and organ cultured corneas used in this study were unsuitable for clinical use due to incomplete donor serology tests or lathing

imperfections. In all cases consent for the use of corneas for either transplantation or research had been obtained. The donor age, the period from death to organ culture, the period in organ culture, and the post-lyophilisation storage times are shown in Table 1. Lenticules were prepared by the dry state lathing technique (Rostron et al. 1988), freeze-dried and stored in vacuum-tight containers at -40°C. The 12 freeze-dried epikeratophakia lenticules used in the study were rehydrated in BSS (Alcon) for 40 minutes

at room temperature. The rehydrated lenticules and three organ cultured corneas were snap frozen using isopentane, chilled to -150°C in liquid nitrogen and cut by cryostat into sections of 6 µm. Fresh tonsillar tissue was processed in the same way and used for positive controls.

In addition, 6 of the lenticules in the study were divided into 3 segments. The first segment was rehydrated as before for 40 minutes, but the second segment was incubated in BSS for a further 24 hours and the third segment for 48 hours. The level of HLA antigens in each segment was then compared.

Table 1. Data regarding donor age, time from death to enucleation, time in organ culture and post lyophilisation storage.

	Donor age in years	Time from death to enucleation in hours	Time in organ culture in days	Post-lyophilisation storage time in months
Organ cultured cornea 1	62	22	27	n/a
Organ cultured cornea 2	62	22	27	n/a
Organ cultured cornea 3	70	18	78	n/a
Lenticule 1	57	12	24	6
Lenticule 2	78	20	60	6
Lenticule 3	64	21	37	7
Lenticule 4	78	20	60	6
Lenticule 5	57	12	24	6
Lenticule 6	64	21	37	6
Lenticule 7	82	18	50	7
Lenticule 8	79	5	62	7
Lenticule 9	61	16	150	30
Lenticule 10	71	42	51	10
Lenticule 11	69	23	91	7
Lenticule 12	63	16	42	7

Table 2. The expression of antigens in controls, stroma of organ cultured corneas and lyophilised lenticules. Positive result (pos) means 100% of nucleated cells were stained, negative (neg) means no or only very occasional cell stained, percentage indicates a proportion of all nucleated cells stained.

	Human leukocyte antigens (HLA)			
	A, B, C	DR	DP	DQ
Positive control 1	pos	pos	pos	pos
Positive control 2	pos	pos	pos	pos
Negative control	neg	neg	neg	neg
Organ cultured cornea 1	pos	10%	neg	neg
Organ cultured cornea 2	pos	missing	neg	neg
Organ cultured cornea 3	pos	missing	neg	<5%
Lenticule 1	pos	<5%	neg	neg
Lenticule 2	pos	30%	<5%	neg
Lenticule 3	pos	20%	neg	neg
Lenticule 4	pos	20%	neg	neg
Lenticule 5	pos	neg	neg	neg
Lenticule 6	pos	20%	neg	neg
Lenticule 7	pos	<5%	neg	neg
Lenticule 8	pos	40%	40%	neg
Lenticule 9	pos	neg	neg	neg
Lenticule 10	pos	<5%	neg	neg
Lenticule 11	pos	neg	neg	neg
Lenticule 12	pos	30%	neg	neg

Immunocytochemistry

Cryostat sections were air dried on Silane coated slides for a minimum of 15 minutes. The slides were fixed in acetone at room temperature for 10 minutes and allowed to dry. Following rehydration in 10% BSA in Tris buffer, the slides were exposed to the primary antisera (mouse monoclonal anti HLA-ABC, DR, DQW1, DQW3, DPW4, DPW2; Sera-lab Inc., Sussex, England; 1:200 dilution in 10% BSA/Tris) for 30 minutes. The sections were then washed in Tris buffer, incubated in a biotinylated second layer (rabbit anti-mouse immunoglobulin; Sera-lab; 1:200 dilution), washed in Tris buffer and an avidin-biotin complex applied for 30 minutes before washing and staining with diaminobenzidine (DAB) and haematoxylin. The slides were examined by light microscopy, a positive reaction being indicated by a red/brown colour. Negative control sections underwent the above procedure apart from incubation with the primary antibodies.

Assessment

Sections were examined in a masked fashion as to antigen and type of corneal tissue, and reported independently by CC and EM. Discrepancies between the two reports were no greater than 10%, so the results presented in Table 2 are those reported by CC.

Epithelial and endothelial cells (if present) were assessed for the presence of all antigens. In the stroma, the percentage of positively stained cells as a proportion of all nucleated cells seen in the sections was reported.

Results

The results of individual slides are shown in Table 2.

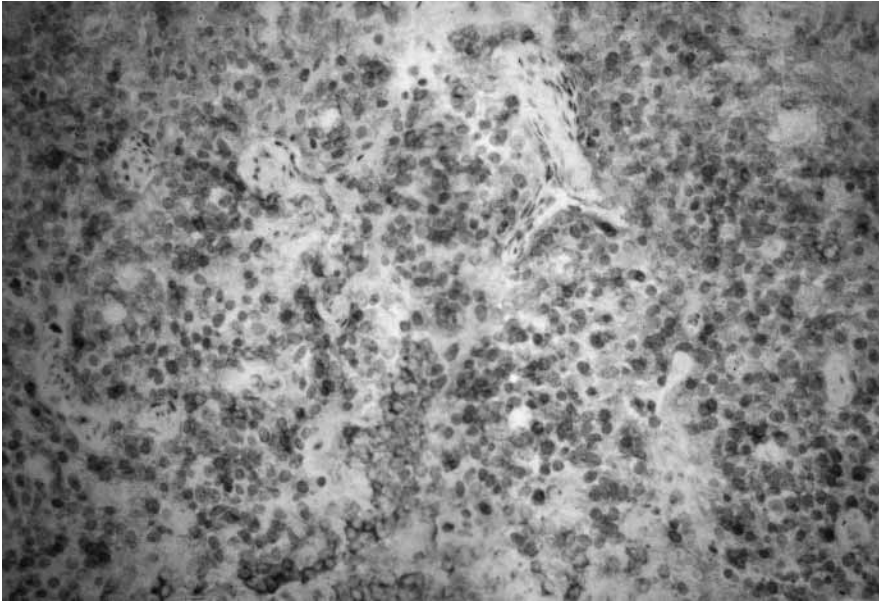


Fig. 1. Fresh tonsillar lymphoid tissue – Positive staining for DQW1, similar pictures were seen in the other positive controls (stained with diaminobenzidine and haematoxylin, light microscopy, $\times 64$).

Controls – Histocompatibility antigens ABC, DR, DQW1 and DPW2, DPW4 were detected in significant amount in the fresh tonsillar tissue (Fig. 1). None of the negative control slides demonstrated a reaction.

Organ cultured corneas – HLA-ABC



Fig. 2. Organ cultured cornea – Stromal keratocytes show positive reaction for HLA-ABC. HLA I (ABC) is also present in the epithelium (stained with diaminobenzidine and haematoxylin, light microscopy, $\times 64$).

were detected on 100% of the stromal keratocytes and about 10% of cells demonstrated positive reaction for HLA-DR antigens, the remaining antigens were not detected. The epithelium, where present (in 2 corneas), demonstrated a strong positive reaction for class I (Fig. 2), but epithelial staining for class II was questionable. Presence of antigens on the endothelium could not be assessed due to paucity of cells in this layer.

Epikeratophakia lenticules – HLA-

ABC antigens were detected on the pyknotic-appearing stromal keratocytes in the rehydrated lenticules (Fig. 3). The antigen staining appeared not as strong as in the organ cultured corneas, but the significance of this is uncertain since the technique is not designed to be quantitative. HLA-DR antigens were found on the keratocytes in the stroma of 9 lenticules with levels ranging from 5–70% of the cells staining positively (Fig. 4). HLA-DQ and DP were present on only very occasional cells in some lenticules (Fig. 5), except for one lenticule where DP antigen was detected on 40% of cells.

Washed epikeratophakia lenticules – The segments of lenticules that were further incubated in BSS for 24 or 48 hours did not demonstrate a change in their antigenic expression (Fig. 6). Haematoxylin and eosin staining demonstrated some stromal disorganisation and further cellular disintegration.

Discussion

As expected, the control tonsillar tissue stained for all class I and class II antigens, but showed no staining in the negative control specimen.

During processing of the epikeratophakia lenticules, the epithelium is manually stripped and the endothelium is removed by the lathing process, so these layers are not transplanted and were not seen on the lenticules apart from occasional residual basal epithelial cell rem-

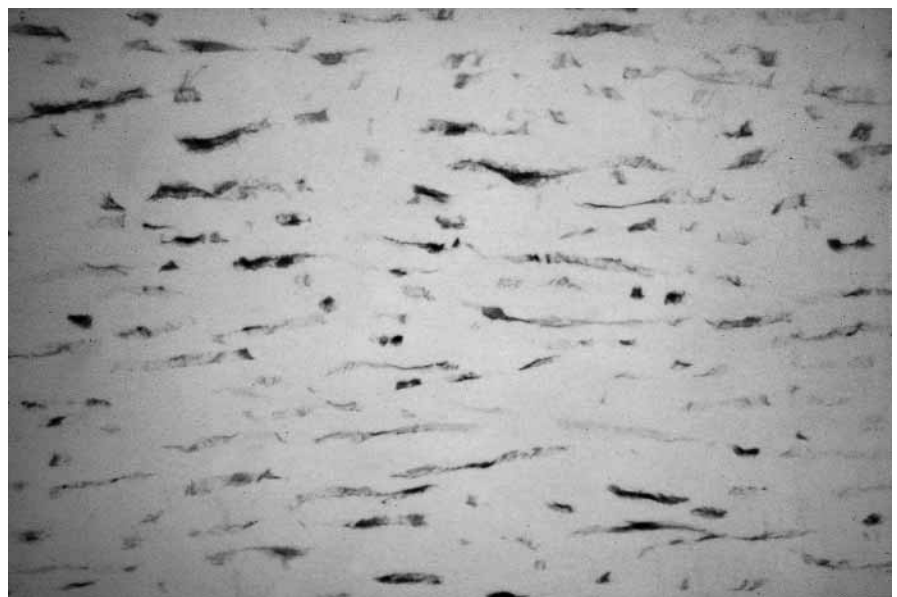


Fig. 3. Lyophilised corneal lenticule – Positive reaction in the stromal keratocytes for HLA-ABC (stained with diaminobenzidine and haematoxylin, light microscopy, $\times 64$).

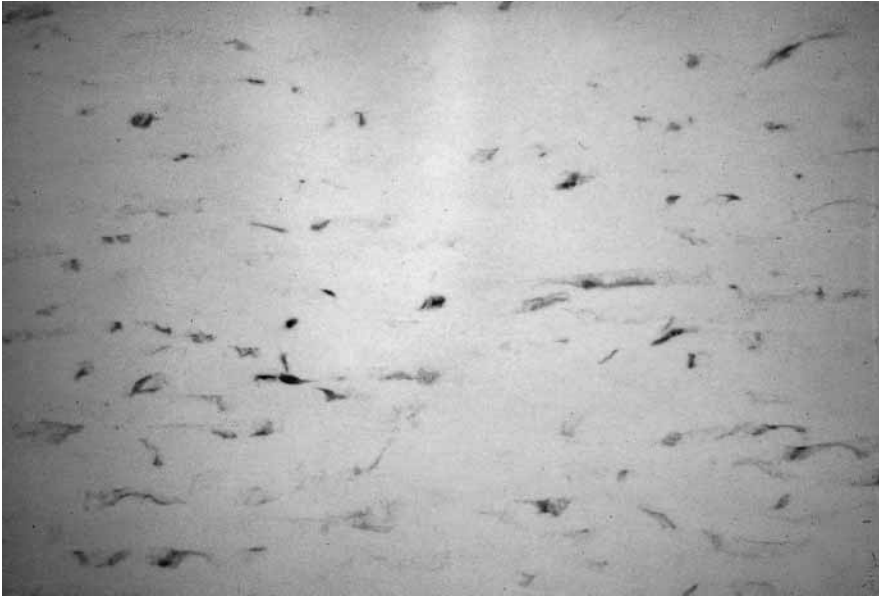

Fig. 4. Lyophilised corneal lenticule – About 70% of nucleated stromal cells show positive reaction for HLA-DR (stained with diaminobenzidine and haematoxylin, light microscopy, $\times 64$).



Fig. 5. Lyophilised corneal lenticule – Negative reaction for HLA-DQW1 with only very occasional cells stained (stained with diaminobenzidine and haematoxylin, light microscopy, $\times 64$).

nants. Keratocytes in organ cultured corneas and epikeratophakia lenticules showed positive staining for HLA class I, as expected. A variable degree of staining for some class II antigens in both organ cultured corneas and lenticules was noted, although this finding has not been reported before. Previous workers have not seen class II antigens on keratocytes in fresh corneas (Pels & van der Gaag 1984), nor in corneas preserved in McCarey-Kaufman medium (Whitsett & Stulting 1984). Class II antigens have been

seen on Langerhans cells in the corneal epithelium close to the limbus, and on cells in the stroma just under Bowman's membrane, but these were found to disappear after a week in organ culture (Pels & van der Gaag 1984), and it has been inferred that for this reason preservation in organ culture might reduce the antigenicity of corneas.

We used an organ culture system similar to Pels (Pels & van der Gaag 1984), but preserved the corneas for much longer periods of time (Table 1) and this



Fig. 6. Lyophilised corneal lenticule after 24 hours incubation in BSS – No apparent change in the expression of HLA-ABC antigens. Stromal disorganisation following prolonged incubation in BSS. Positive staining seen in residual epithelial cell debris (stained with diaminobenzidine and haematoxylin, light microscopy, $\times 100$).

may possibly account for the variation of our results from the previously published findings. It has been shown that class II antigens can be seen on keratocytes of rejected corneal graft tissue (Pepose et al. 1985), and in addition, cultured human keratocytes have shown class II antigen expression on 40–70% of cells grown in vitro after stimulation with γ interferon (Young et al. 1985). Alternative explanations for the discrepancy between our findings and those of previous reports are a difference in the sensitivity of our monoclonal antibody system, or variation in the organ culture conditions which might have altered the level of antigen expression.

The proportion of cells expressing antigen was no different in the organ cultured corneas from that in the lathed lyophilised lenticules. In this our results concur with those of Pepose et al. (Pepose & Benevento 1991) in that lyophilised epikeratophakia lenticules do not lose their antigenic expression as a result of the manufacturing process. HLA antigens can be detected on the remnants of keratocytes but the presence of antigens alone is probably not sufficient to stimulate an immune rejection. The viability of

the cells is probably essential as they are thought to take active part in the process of allograft rejection. However, since the keratocytes are non-viable following lyophilisation their immunogenicity is thought to be minimal.

Watanabe and Tsutsui suggested that mild denaturation of corneal proteins such as that occurring during lyophilisation, or removal of water soluble proteins by immersion of the graft in glycerol isotonic saline produces a reduction of antigenicity (Watanabe & Tsutsui 1962). Our results do not support the suggestion that prolonged incubation of lyophilised lenticules with BSS reduces their antigenicity through a reduction of antigenic expression on the keratocytes. We observed, however, that it causes further stromal disorganisation and cellular disintegration in these lenticules.

Conclusions

This is the first study of antigenic expression of keratocytes in corneal lenticules produced by dry state lathing and lyophilisation. This method of processing the corneal tissue does not appear to influence the antigenic expression, nor did prolonged washing of the lenticules alter the situation.

However, in this study we found a variable degree of expression of class II antigens on the keratocytes. This has not previously been reported in normal corneas. It is not clear whether this finding is related to prolonged organ culture preservation or to methodological differences in our immunocytochemistry technique.

Acknowledgements

This work was funded by a grant from the St. George's Hospital Trustees, with support from the Keratec Eye Bank (Registered Charity No: 803386).

The authors also wish to thank Professor P. Noel Dilly, Mr. Peter Dalton and Ms. Doreen Lewis for their assistance with this project.

References

- Bourne WM (1975): Antigenicity of cryopreserved corneas. *Arch Ophthalmol* 93: 215–218.
- Chau GK, Dilly SA, Sheard CE & Rostron CK (1992): Deep lamellar keratoplasty on air with lyophilised tissue. *Br J Ophthalmol* 76: 646–650.
- Frantz JM, Limberg MB, Kaufman HE & McDonald MB (1988): Penetrating keratoplasty after epikeratophakia for keratoconus. *Arch Ophthalmol* 106: 1224–1227.
- Frantz J, McDonald MB & Kaufman HE (1989): Results of penetrating keratoplasty after epikeratophakia for keratoconus in the nationwide study. *Ophthalmology* 96(8): 1157–1159.
- Frantz JM, Gebhardt BM, Reidy JJ & McDonald MB (1991): Immunogenicity of epikeratophakia tissue lenses containing living donor keratocytes. *Refract Corneal Surg* 7: 141–145.
- Moore MB, Gebhardt BM, Verity SM & McDonald M (1987): Fate of lyophilized xenogeneic corneal lenticules in intrastromal implantation and epikeratophakia. *Invest Ophthalmol Vis Sci* 28: 555–559.
- Pels V & van der Gaag R (1984/1985): HLA-A, B, C and HLA-DR antigens and dendritic cells in fresh and organ culture preserved corneas. *Cornea* 3: 231–239.
- Pepose JS, Gardener KM, Nestor MS, Foos RY & Pettit TH (1985): Detection of HLA class I and II antigens in rejected human corneal allografts. *Ophthalmology* 92: 1480–1484.
- Pepose JS, Benevento WJ (1991): Detection of HLA antigens in human epikeratophakia lenticules. *Cornea* 10: 105–109.
- Rostron CK, Sandford-Smith JH & Morton DB (1988): Experimental epikeratophakia using tissue lathed at room temperature. *Br J Ophthalmol* 72: 354–360.
- Rostron CK (1996): Introduction to epikeratophakia. In: Claoué C (ed). *Laser and conventional refractive surgery*. 8: 157–209. BMJ Publishing Group, London.
- Watanabe S, Tsutsui J (1962): Immunochemical alteration of proteins in lyophilized corneal heterografts. *Arch Ophthalmol* 67: 78–85.
- Whitsett CF & Stulting RD (1984): The distribution of HLA antigens on human corneal tissue. *Invest Ophthalmol Vis Sci* 25: 519–524.
- Young E, Stark WJ & Prendergast RA (1985): Immunology of corneal allograft rejection: HLA-DR antigens on human corneal cells. *Invest Ophthalmol Vis Sci* 26: 571–574.
- Zavala EY, Binder PS & Deg JK (1985): Refractive keratoplasty: lathing and cryopreservation. *CLAO J* 11: 155–162.

Received on October 24th, 1997.

Accepted on April 2nd, 1998.

Corresponding author:

Mr Chad K. Rostron, FRCOphth
Department of Ophthalmology
St. George's Hospital
London SW17 0QT
England

Tel: 44 181 725 2325

Fax: 44 181 725 3026

e-mail: rostron@sghms.ac.uk